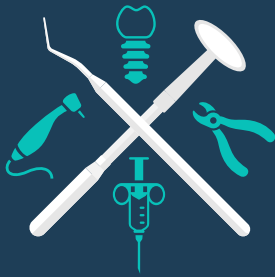

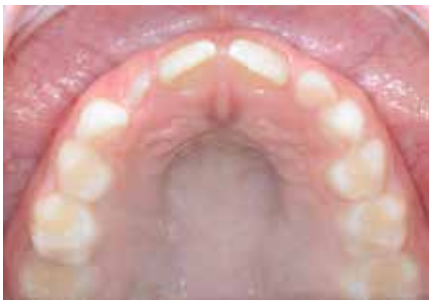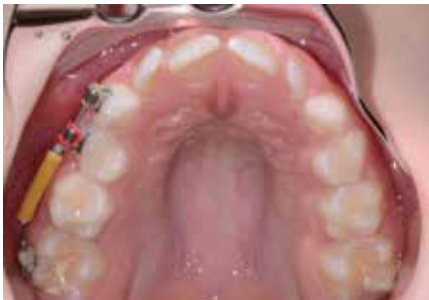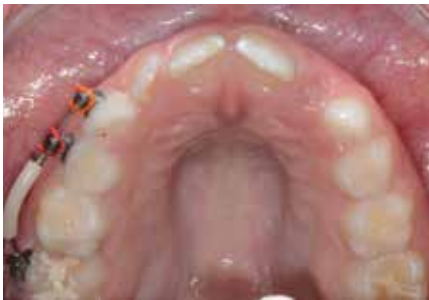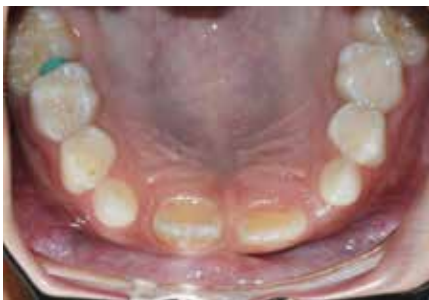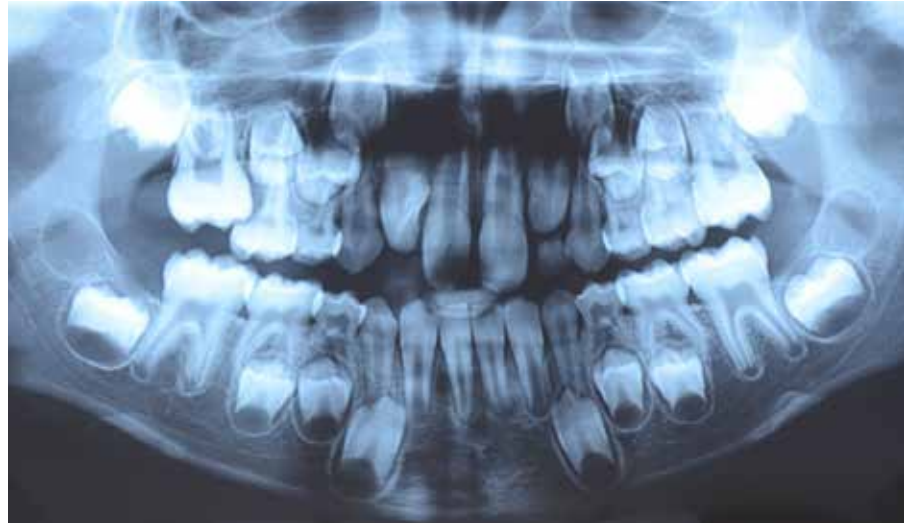
CLINICAL TIPS



AND EXTRACTS

Ectopic maxillary first molars: please do not extract the E!

By Dr Nour Eldin Tarraf



Often in the early mixed dentition a maxillary first permanent molar erupts ectopically and is locked or impacted under the deciduous second molar. Too often those patients are referred after the deciduous second molar has been extracted because it is deemed "too badly" damaged. The first molar then erupts mesially taking up most of the space for the second premolar. We are then left with the dilemma of opening space and maintaining it for four to five years until eruption of the second premolar or planning for later complicated treatment with potential extraction of the second premolar. This is almost always avoidable if the 6s are managed correctly and timely. Ectopic eruption of first molars is fairly common and it can self-correct in many cases. However, extraction of the E (deciduous second molar) is almost never a good idea. Studies show that the E will survive till the normal shedding time even with advanced resorption of the distal root, if the 6s are disimpacted with an appropriate treatment in a timely manner^[1, 2].

The management will depend on the degree of impaction^[3], presence or absence of the 5s, crowding and other factors. Management can be as simple as placement of an elastomeric or metallic separator, which can be enough to disimpact the 6, all the way up to a sectional fixed appliance to push the 6s distally.

Early detection and management is key. Children should be monitored for the timely eruption of the first permanent molars between 5-7 years old. If ectopic first molars are detected early management can save a lot of treatment time and cost in trying to regain space and then maintain it until the eruption of the second premolar.

References:

1. Kurol J, Bjerklin K: Resorption of maxillary second primary molars caused by ectopic eruption of the maxillary first permanent molar: a longitudinal and histological study. *ASDC J Dent Child* 1982, 49:273-279.
2. Kurol J, Bjerklin K: Ectopic eruption of maxillary first permanent molars: a review. *ASDC J Dent Child* 1986, 53:209-214.
3. Kennedy DB, Turley PK: The clinical management of ectopically erupting first permanent molars. *Am J Orthod Dentofacial Orthop* 1987, 92:336-345.

Dr Tarraf is presenting Understanding Orthodontics at the ADA NSW Centre for Professional Development on 30 May, 9.00am-4.30pm, 1 Atchison Street, St Leonards. Book online at www.adansw.com.au/CPD